



Gossypiboma - Rare Cause of Rectovaginal Fistula: A Case Report

Neeraj Saxena¹, Rohit Chauhan^{1*} and Tayod Kumar Choudhary¹

¹*Department of General and Minimally Invasive Surgery, Atal Bihari Vajpayee Institute of Medical Sciences & Dr RML Hospital, New Delhi, India.*

Authors' contributions

This work was carried out in collaboration among all authors. Authors NS and RC designed the case study and wrote the first draft of the manuscript. Author TKC performed the statistical analysis and managed the literature searches. All authors read and approved the final manuscript.

Article Information

Editor(s):

(1) Dr. Yasushi Shibata, University of Tsukuba, Japan.

Reviewers:

(1) Morteza Fallah-Karkan, Shahid Beheshti University of Medical Science, Iran.

(2) Guillermo Padrón Arredondo, General Hospital Palya del Carmen, Mexico.

Complete Peer review History: <http://www.sdiarticle4.com/review-history/60934>

Case Study

Received 30 June 2020
Accepted 05 September 2020
Published 11 September 2020

ABSTRACT

Gossypiboma is the term used when a surgical sponge is left unknowingly in the patient's body after a surgical procedure. It is a grave but preventable complication of surgery which can lead to serious medico-legal complications. It may either present early with/without lump formation or may remain asymptomatic for a long time with only vague symptoms. However, gossypiboma leading to the formation of a rectovaginal fistula is extremely rare.

We report a case of a 40-year lady who presented with vague pain abdomen and passage of stools and flatus per vagina. She had a history of total abdominal hysterectomy eight months back done at an outside hospital. A computed tomography (CT) revealed a retained surgical sponge and a fistulous tract between the rectum and vagina. Exploratory laparotomy was done at our institution and the surgical sponge was extracted from a mass comprising of distal ileum and sigmoid colon. Bowel continuity was restored with an ileal diversion.

Keywords: *Gossypiboma; rectovaginal fistula; retained surgical sponge.*

*Corresponding author: E-mail: rohitchauhan93@yahoo.com;

1. INTRODUCTION

Gossypiboma is a rare surgical complication that can lead to significant morbidity to the patient and can also lead to medico-legal issues. It is an expression used to describe a surgical sponge left unknowingly in the patient's body after a surgical procedure. The word gossypiboma is derived from a combination of the Latin word 'Gossypium' meaning cotton, and Swahili word 'boma' meaning place of concealment [1]. Most cases are found within the first few days after surgery but they may remain hidden without any symptoms for many years [2]. Surgical treatment is usually the only option in such cases.

2. CASE REPORT

A 40-years lady presented with the complaint of pain in the left lower abdomen which was dull aching, non-radiating, and progressively increasing in intensity for the past four months. The patient also complained of passage of stools and flatus per vagina for past two months. Patient gave a history of total abdominal hysterectomy 8 months back at another health centre following which she developed RVF. A transverse colostomy was also made at the same health centre, to divert stools away from the RVF. Patient had no other comorbidity. Vitals were within normal limits. On examination of the abdomen, a transverse colostomy was present in the right upper quadrant and a horizontal scar of previous hysterectomy was visible in the hypogastrium. The abdomen was soft, non-tender, and there was no palpable lump/swelling. On per rectal examination, the anal tone was

normal, the lumen was collapsed and faecal staining was present. There was no fistulous opening visible on proctoscopy. Per vaginal examination showed an intact vaginal vault but no fistula was demonstrable. Rest of the systemic examination was unremarkable. Routine blood investigations showed normal values. A computed tomography (CT) with oral, intravenous, and rectal contrast was done which revealed a relatively well circumscribed oval shaped hypodense lesion of size approximate dimensions of 9.9 x 8.6 x 6.7 cms in the pelvic cavity superior to the dome of bladder [Fig. 1]. It had a heterogenous spongiform appearance with multiple air pockets within and a surrounding thickened enhancing capsule suggestive of gossypiboma. Mild, diffuse, circumferential, enhancing, mural thickening was also seen involving the ileocaecal junction causing mild luminal narrowing in the terminal ileum. On giving rectal contrast, it was seen surrounding the lesion suggesting its intraluminal location. A thin, curvilinear, fistulous tract was visible, approximately 3.1 mm in maximum thickness and 3 cm in length, extending between the distal sigmoid colon and vaginal vault. A colonoscopy was done and at 15 cm from anal verge, few sutures along with a fistulous opening was seen. The procedure was abandoned since the lumen was loaded with faeces.

The patient was taken up for laparotomy. Intra-operatively, a large clump formed by the surgical sponge involving the sigmoid colon and terminal ileum, was found [Fig. 2]. An ileocolic fistula was present between the sigmoid colon and terminal ileum (at approximately 40 cm from the

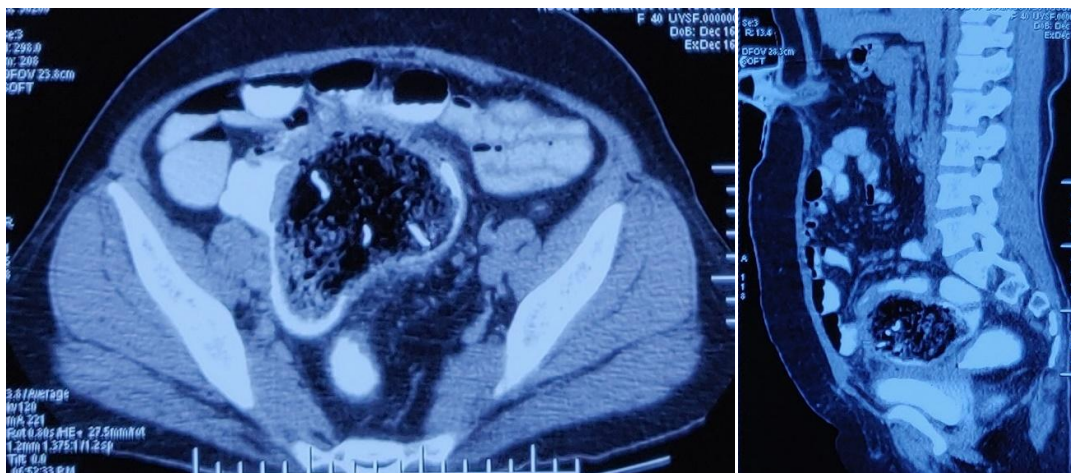


Fig. 1. CT scan (axial and sagittal view) showing spongiform lesion suggestive of Gossypiboma

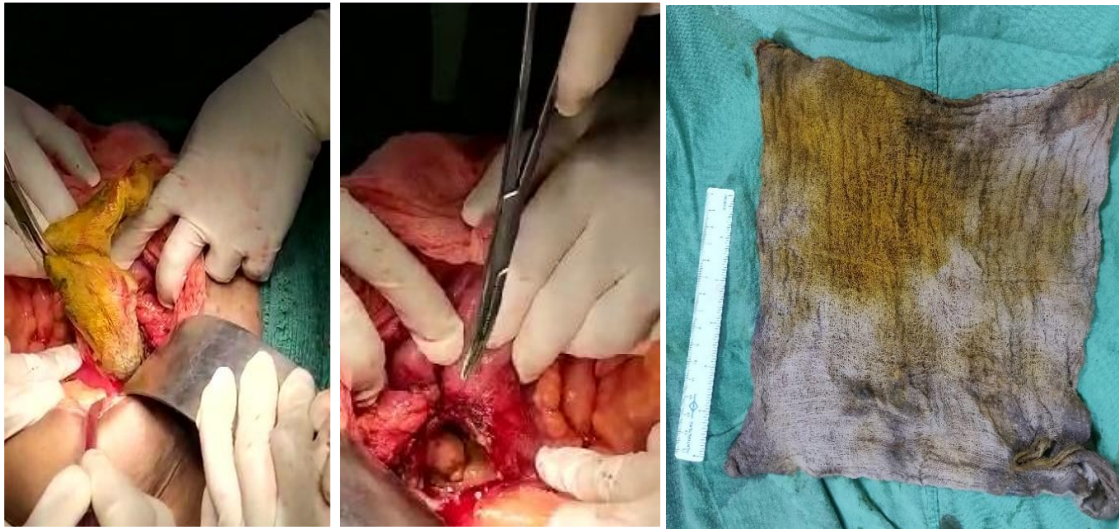

Fig. 2. Surgical sponge extracted from the lumen of bowel

ileocaecal junction) – explaining the presence of faeces in the rectum despite diversion colostomy. The sponge was present in the lumen of both terminal ileum and sigmoid colon. The fistula tract could not be approached due to dense fibrosis in the region.

After the removal of the sponge, there was a large defect in the sigmoid colon of size approximately 6 cm x 4 cm and a defect in the distal ileum at approx. 40 cm from the ileocolic junction of size 3 cm x 2 cm. To restore the bowel continuity, 10 cm of sigmoid colon was resected and an end-to-end transrectal stapled colorectal anastomosis using circular stapler number 33 was done, akin to a low anterior resection procedure in the rectum. The transverse colostomy was dismantled and closed. The involved ileum was resected and the two ends brought out as a double barrel ileostomy to divert the ileal contents in order to facilitate the healing of the distal colorectal anastomosis. The patient was discharged without any complication on 6th post-op day. A distal loopogram done at an eight week follow up was unremarkable. There was no spillage of contrast into the vagina suggesting healed recto-vaginal fistula. The double barrel ileostomy was dismantled and closed. Patient had no symptoms of RVF on further follow up at 12 weeks.

3. DISCUSSION

Gossypiboma or retained surgical sponge is an uncommon surgical complication and has a reported incidence of 1 in approximately 1000–

1500 abdominal surgeries [3]. However, it is difficult to make out the actual incidence on account of the under-reporting due to the fear of medicolegal implications [4,5]. A retained surgical sponge is most commonly seen following emergency surgeries. The contributing causes may be a change in the surgical procedure, change in nursing staff team, hurried sponge counts, prolonged surgeries, obese patient, unstable patient, inexperienced staff, and inadequate staff numbers [6].

Radiological investigations such as x-rays, ultrasound, computed tomography, and magnetic resonance imaging are useful in the diagnosis of gossypiboma [7]. Typical CT sign suggestive is a well circumscribed mass with thick wall and whorl like or spongiform internal structure, attributable to the presence of gas trapped inside the sponge [8]. Absence of a radiological marker over the sponge can sometimes make the diagnosis difficult because the cotton can simulate hematoma, abscess, cystic mass, or a neoplasm [6]. Thus, gossypiboma should be kept as a differential in such patients with undiagnosed pain abdomen, discomfort, previous history of surgery and a diagnostic dilemma on radiological investigations.

Treatment is usually by surgical removal of the sponge. Endoscopic or laparoscopic approaches may be attempted; however, such an approach may be difficult due to the intense foreign body reaction and dense adhesion formed around the surgical sponge, similar to what was seen in our case.

Two different biological responses are triggered due to the retained sponge. An exudative reaction leading to abscess formation or an aseptic fibrinous response due to foreign body granuloma [9]. The patient may present early with pain or may remain asymptomatic with only vague symptoms depending upon the location, size of the sponge, and the type of reaction that occurs. Inflammatory reaction caused by a retained surgical sponge in the peritoneal cavity can erode and perforate the wall of a luminal organ [5,10]. Transmural migration of a sponge in luminal organs can cause bleeding, anemia, obstruction or acute abdominal pain [11,12].

Cases in which transmural migration of the sponge occurred, have been reported in the past but RVF as a result of a retained surgical sponge has not been reported in literature. In our case, the gossypiboma caused vague abdominal pain initially and then later presented in the form of RVF. Prevention of gossypiboma is of utmost importance which can be done by a thorough sponge count before and after the procedure, use of a sponge with radio-opaque markers, and strictly following the surgical safety checklist.

4. CONCLUSION

Gossypiboma is a rare and serious, but preventable complication of surgery. It causes significant morbidity to the patient and can lead to serious medicolegal issues. Therefore, all necessary precautions should be undertaken to prevent such a complication. The surgeons should use sponge with radiological markers and a strict sponge count should be kept before and after the surgery. Gossypiboma should be included in the differential diagnosis in patients with undiagnosed pain abdomen, discomfort, and a previous history of surgery.

CONSENT

Written informed consent was obtained from the patient for publication of this case report and accompanying images.

ETHICAL APPROVAL

As per international standard or university standard written ethical approval has been collected and preserved by the authors.

COMPETING INTERESTS

Authors have declared that no competing interests exist.

REFERENCES

1. Rajput A, Loud PA, Gibbs JF, Kraybill WG. Diagnostic challenges in patients with tumors: Case 1. Gossypiboma (foreign body) manifesting 30 years after laparotomy. *J Clin Oncol.* 2003;21(19):3700-3701. DOI: 10.1200/JCO.2003.02.092
2. Colak T, Olmez T, Turkmenoglu O, Dag A. Small bowel perforation due to gossypiboma caused acute abdomen. *Case Reports in Surgery.* Article ID 219354. 2013;2013:3.
3. Zejnnullahu VA, Bicaj BX, Zejnnullahu VA, Hamza AR. Retained surgical foreign bodies after surgery. *Open Access Maced J Med Sci.* 2017;5(1):97-100. DOI: 10.3889/oamjms.2017.005
4. Uluçay T, Dizdar MG, SunayYavuz M, Aşirdizer M. The importance of medico-legal evaluation in a case with intraabdominal gossypiboma. *Forensic Sci Int.* 2010;198(1-3):e15-e18. DOI: 10.1016/j.forsciint.2010.01.013
5. Agrawal H, Gupta N, Krishengowda U, Gupta AK, Naskar D, Durga CK. Transmural Migration of Gossypiboma: A Rare Cause of Acute Abdomen. *Indian J Surg.* 2018;80:84–86. Available: <https://doi.org/10.1007/s12262-017-1660-9>
6. Lata I, Kapoor D, Sahu G. Gossypiboma, a rare cause of acute abdomen: a case report and review of literature. *International Journal of Critical Illness and Injury Science.* 2011;1(2):157–160.
7. Malhotra MK. Migratory surgical gossypiboma-cause of iatrogenic perforation: case report with review of literature. *Nigeria Journal of Surgery.* 2012; 18(1):27–29.
8. Malik A, Jagmohan P. Gossypiboma: US and CT appearance. *Indian J Radiol Imaging.* 2002;12: 503-4.
9. Gibbs VC, Coakley FD, Reines HD. Preventable errors in the operating room: retained foreign bodies after surgery—part I. *Current Problems in Surgery.* 2007; 44(5):281–337.
10. Kassi A, Yenon K, Koffi E. A transmural migration of a gossypiboma in the right colon responsible for a mass which mimicked an abscessed colonic tumor: A case report. *International Journal of Surgery Case Reports.* 2018;51:228–230.

- Available: <https://doi.org/10.1016/j.ijscr.2018.08.046>
11. Colak T, Olmez T, Turkmenoglu O, Dag A. Small bowel perforation due to gossypiboma caused acute abdomen. Case Rep. Surg; 2013;219354.
- Available: <http://dx.doi.org/10.1155/2013/219354>
12. Javanmard B, Yousefi MR, Fadavi B, Fallah Karkan M. Retained surgical gauze presenting with gross hematuria: A case report. Urol. J. 2017;14:5027–5029.

© 2020 Saxena et al.; This is an Open Access article distributed under the terms of the Creative Commons Attribution License (<http://creativecommons.org/licenses/by/4.0>), which permits unrestricted use, distribution, and reproduction in any medium, provided the original work is properly cited.

Peer-review history:
The peer review history for this paper can be accessed here:
<http://www.sdiarticle4.com/review-history/60934>